
RETINA TODAY

ENDPOINT MANAGEMENT: NON-DAMAGING LASER THERAPY OF THE MACULA

Sponsored by Topcon



The Scientific Rationale for Non-Damaging Retinal Laser Therapy

Preclinical experiments have defined the range of laser energies, which elicit cellular stress response below the RPE damage threshold. Endpoint Management provides reliable titration of the laser for treatment within the non-damaging therapeutic window in every patient.

BY DANIEL PALANKER, PhD; STANFORD UNIVERSITY, PALO ALTO, CA

Light falling on the retina is absorbed primarily by melanin and blood. For yellow and green wavelengths, about 5% of the energy is absorbed in the nearly-transparent neural retina, about 45% in the retinal pigment epithelium (RPE), and the rest in the choroid. Therefore, retinal heating and coagulation is governed primarily by heat diffusion from the pigmented layers, which absorb laser energy. Duration of the laser exposure defines how deep the heat wave will penetrate into the retina during the laser pulse. Thus, the size of the affected zone is a function of not only the laser spot width, but also the power and pulse duration.

Heating of biomolecules leads to their denaturation, which, above a certain threshold, can result in cellular necrosis and coagulation. Dynamics of denaturation can be described as a chemical reaction, with its rate scaling as an exponential function of temperature (Arrhenius equation). The total amount of thermal damage at every point in the tissue can then be calculated as an integral, known as the Arrhenius integral, of the denaturation rate over the duration of hyperthermia in that point. The Arrhenius integral is typically normalized to unity at the cellular damage threshold (exposures with Arrhenius integral W less than 1 are sublethal). Different clinical grades of retinal lesions correspond to different levels of Arrhenius integral: in barely visible lesions, W reaches approximately 1000, in lesions visible only in OCT the W peaks at about 100, etc.

THE ENDPOINT MANAGEMENT ALGORITHM

Conventional retinal burns damage RPE cells, coagulate photoreceptors, and intense burns even damage the inner retina. Such burns typically result in retinal scarring and preclude retreatments.

Endpoint Management (EpM, Topcon) technology was developed to enable delivery of the well-defined

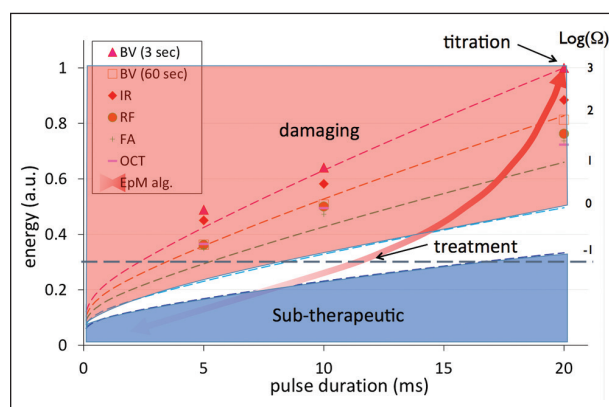


Figure 1. Endpoint Management is a non-damaging retinal laser therapy that uses a the Arrhenius integral algorithm to control laser power and pulse duration, optimizing the therapeutic effect of the laser at sub-visible levels. Laser settings above the Arrhenius integral of 1 ($\log \Omega = 0$) correspond to tissue damage. Laser settings below the $\Omega = 0.1$ ($\log \Omega = -1$) are sub-therapeutic.

thermal effects to the retina even below the threshold of visible changes in the tissue. EpM converts the highly nonlinear scale of Arrhenius integral into linear steps of pulse energy by adjusting laser power and duration such that a 20% change in pulse energy corresponds to a factor of 10 change in Arrhenius integral, as shown in Figure 1. To ensure precise dosing in every patient, despite variation in pigmentation and tissue transparency, EpM algorithm begins with titration of the laser power to produce barely visible burns in the retina outside the arcade using 15 or 20 ms pulse duration. Laser energy corresponding to this power is then defined as 100%.

At 75% laser energy, the lesions are not visible ophthalmoscopically, but photoreceptors damage can be seen in OCT. At 50% energy, they might not be visible in

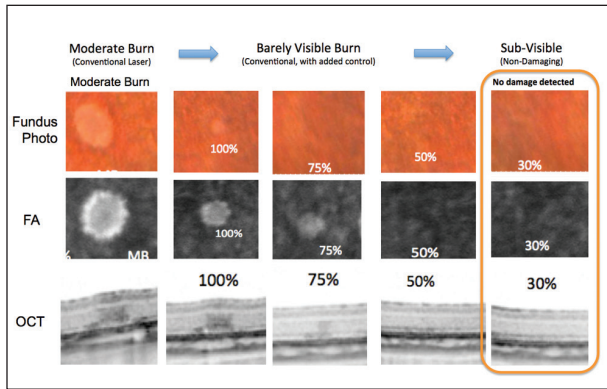


Figure 2. There is no damage detectable on histology, nor on FA or OCT when using EpM.

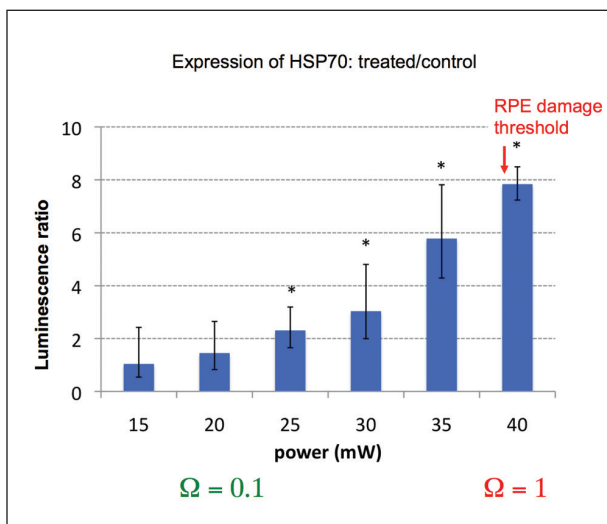


Figure 3. HSP-70 is upregulated even below the RPE damage threshold, down to Arrhenius integral $\Omega=0.1$.

OCT, but are still visible in histology, and RPE damage is detectable using fluorescein angiography (FA). However, at 30% energy, there is no damage detectable on histology, nor on FA or OCT (Figure 2).¹

TISSUE RESPONSE BELOW DAMAGE THRESHOLD

To explore whether retinal cells respond to thermal stress below the damage threshold, we first used transgenic mice, which express bioluminescent marker attached to the heat shock protein 70 (HSP-70). We discovered that HSP-70 was upregulated even below the damage threshold, down to Arrhenius integral of $\Omega=0.1$, as shown in Figure 3. Using immunohistochemistry, we observed expression of HSP-70 in the RPE at energy levels of 30% and 25%, with very little response at 20%. With conventional photocoagulation burns, HSP-70 is detectable in the ring of cells surrounding the damage zone, whereas in nondamaging exposures produced at 30% energy and below, HSP-70 is detectable in the middle of

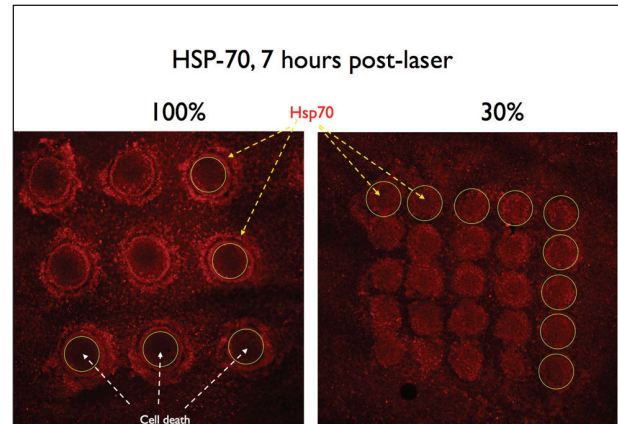


Figure 4. HSP-70 expression in laser spots with 100% energy (barely visible burns) on the left and with 30% energy on the right. Note the presence of HSP-70 at the periphery of traditional laser burns (surrounding the areas of cell death) but in the center of those produced with non-damaging exposures.

Animal experiments demonstrated that 30% energy on EpM scale does not produce any signs of damage on the retina. This was confirmed in clinical trials.

the spot, with no evidence of cell death (Figure 4).²

HEAT SHOCK PROTEINS

Misfolding and aggregation of proteins in cell is a fundamental component of aging. As chaperones, heat shock proteins normally refold the damaged proteins and thereby protect cells from protein aggregation and associated toxicity. However, transcriptional pathways decline with aging, leading to protein aggregation, commonly observed in neurodegenerative diseases. Induction of HSP in aging cells promotes longevity and rejuvenates cellular functions. In addition, molecular chaperones, such as HSP27 and HSP70, have anti-apoptotic functions. Therefore, enhanced synthesis of HSP and co-chaperones in response to laser-induced thermal stress in RPE can normalize physiology of these cells in aging and disease, including enhanced capability of fluid pumping from the retina and control of chorioidal permeability.

RATIONAL FOR NONDAMAGING RETINAL LASER THERAPY

Mechanisms leading to therapeutic benefits of the

Lack of tissue damage allows high density treatment to boost therapeutic response and periodic retreatments, which are essential in management of chronic diseases.

laser photocoagulation in the macula have never been established. If we hypothesize that the benefits originate from the response of cells surviving the hyperthermia at the edges of the damage zone, such response could be replicated without tissue damage. This can be accomplished by titrating the laser energy into the range of cellular response to thermal stress below the damage threshold, which is at 30% on the EpM scale.

To ensure efficient tissue response, the treatment should be applied in a dense pattern, with laser spots separated by about one-quarter of the spot diameter. EpM was developed with retinal laser spot diameter of 200 μm , currently being used clinically. Smaller spot sizes are not recommended since (a) EpM is not calibrated for smaller spots, and (b) smaller, barely visible lesions are hard to detect. Even with 200 μm spots, typical macular treatment requires about 400 to 500 exposures. With 100 μm spots, it would require four times larger the number of pulses, which would be difficult to deliver within a few minutes of treatment.

Treatment of the patients with chronic central serous chorioretinopathy using EpM demonstrated that 30% energy does not produce any signs of damage on the retina or RPE. Subretinal fluid was resolved completely in 81% of patients, and partially in 19% of the patients,

without any nonresponders. Choroidal and retinal thickness decreased to normal levels and visual acuity improved by 12 ETDRS letters within 2 months of the treatment.³ Importantly, lack of tissue damage allows high density treatment to boost therapeutic response and periodic retreatments, which are essential in management of chronic diseases.

CONCLUSIONS

Initial clinical experience with non-damaging retinal laser therapy enabled by EpM confirms that the therapeutic window defined in preclinical experiments is indeed below the damage threshold and within the range of therapeutic response in human patients. A non-damaging approach to retinal laser therapy provides an exciting opportunity of treating macular diseases without retinal scarring and other side effects of conventional photocoagulation. This allows for periodic retreatment, which is essential in the management of chronic diseases. Clinical trials continue with chronic central serous chorioretinopathy, diabetic macular edema, edema secondary to BRVO and other retinal diseases. ■

Daniel Palanker, PhD, is a professor in the department of ophthalmology at Stanford University, California. He is the inventor of the patents and consultant to Topcon, OptiMedica (now Abbott Medical Optics), Medtronic, Avalanche Biotechnologies, Oculeve, DigiSight, and Pixium Vision. Dr. Palanker may be reached at palanker@stanford.edu.



1. Lavinsky D, Sramek C, Wang J, et al. Subvisible Retinal Laser Therapy: Titration Algorithm and Tissue Response. *Retina*. 2014; 34(1):87-97.
2. Sramek C, Mackanos M, Spittler R, et al. Non-damaging retinal phototherapy: dynamic range of heat shock protein expression. *Invest Ophthalmol Vis Sci*. 2011;52(3):1780-1787.
3. Lavinsky D, Palanker D. NonDamaging photothermal therapy for the retina: initial clinical experience with chronic central serous retinopathy. *Retina*. 2015;35(2):213-22.

*Treatment is non-damaging based on Endpoint Management parameters

Treatment Success and Safety Using Endpoint Management

Clinical applications of laser treatment for treating diabetic macular edema and central serous chorioretinopathy.

BY DANIEL LAVINSKY, MD; RIO GRANDE DO SUL, BRAZIL

During laser photocoagulation, heat is transferred to the retina and tissue is destroyed to create a therapeutic effect. On fundus photography, it is easy to visualize treatment spots as a whitish lesion (Figure 1), and yet this is only a superficial look at the actual ablative effects of photocoagulation. In fact, photocoagulation produces a damaging effect to all of the retinal layers, potentially damaging the inner retinal and nerve fiber layers during treatment and, in some cases, the vitreous can be affected as well. Given this, it is easy to understand that one complication often associated with laser therapy is post-procedure loss of visual acuity.

Endpoint Management (EpM, Topcon) is designed to allow the user to precisely control the power, exposure duration, and diameter of the laser spot used for treatment. The goal with this system is to deliver enough energy to create an effect without causing unnecessary damage (Figure 1). The word “endpoint” is intentionally used to describe this system, because the operator can reduce laser energy in order to create a predictable extent of tissue damage only at the tissue level of interest. For example, the system can be adjusted so that only the cells of the RPE are affected.

EXPERIMENTAL STUDY

I was involved in a study that looked at how varying laser power and pulse duration could titrate the treatment effect in ocular tissue.¹ We used the PASCAL Streamline 577 laser system to produce a barely visible laser burn in Dutch Belted Rabbits; the laser power needed to create that effect was defined as the 100% energy level. We then adjusted the laser power level to 170%, 120%, 75%, 50%, and 30% of our titration burn and examined for tissue effects at 1 hour and 3, 7, 30, and 60 days after treatment.

Our study demonstrated that tissue damage occurred to the retinal pigment epithelium (RPE) as well as to photoreceptors (and in some cases, to the inner retina) using either 120% or 170% power. At 50% to 70% power, some damage occurred to photoreceptors in addition to the RPE, and burns were visible with fluorescein

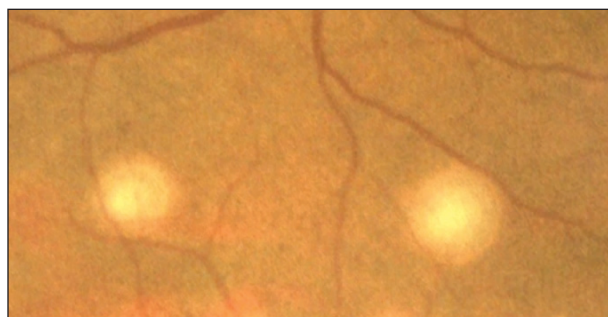


Figure 1. The hallmark whitish appearing lesions characteristic of photocoagulation are easily identifiable on this fundus photograph.

EpM is designed to allow the user to precisely control the power, exposure duration, and diameter of the laser spot used for treatment.

angiography (FA) and optical coherence tomography (OCT). We detected no RPE alteration with power levels below 30% of our titration burn, but between 30% and 50% power, we noted changes only to the RPE on histology samples, and burns were not visible with FA, OCT, or in vivo multimodal imaging.

USING ENDPOINT MANAGEMENT

Because EpM is a new way of performing laser therapy, there may be a slight learning curve when first using the system. Treatment begins by titrating to a barely visible burn placed outside the arcades using 100% power with a pre-determined duration and exposure. Then the power is reduced (for example, to 30%) to create a grid pattern. Users of photocoagulation will notice a stark difference, as there will be no evidence of a burn after treatment that is noticeable on FA, OCT, or clinically. Yet, the absence of visible treatment scars does not mean that nothing has

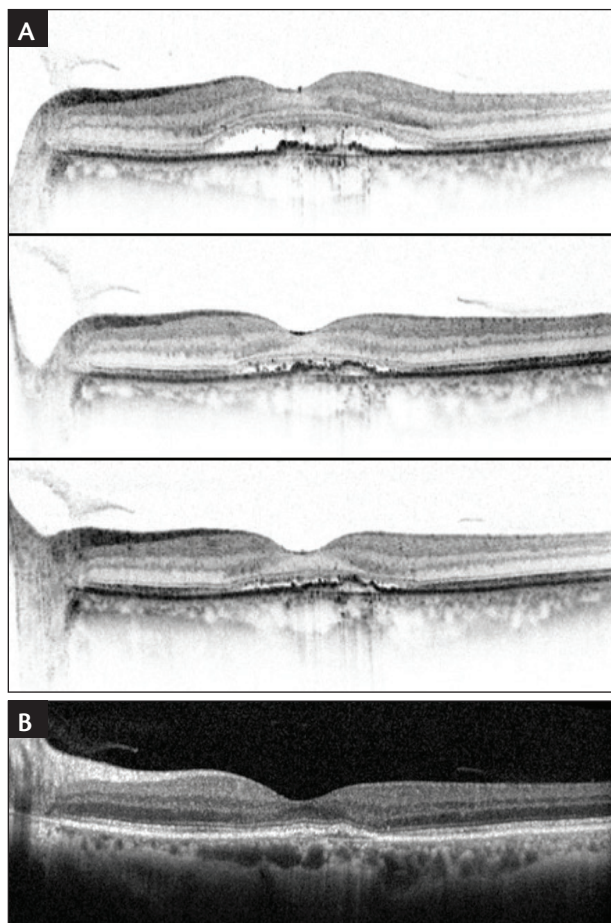


Figure 2. Baseline, 1 month, and 2 month OCT images (A) depicting resolving anatomy and improving visual acuity. By 3 months posttreatment, the patient's anatomy had resolved and the visual acuity was 20/20 (B).

occurred. Data from experimental studies and early clinical experience suggests that barely visible laser treatment can be highly effective at restoring the anatomy and improving visual acuity.

CSR AND EPM PILOT STUDY

I was involved in a pilot study that demonstrated the effect of using EpM in 16 eyes being treated for central serous chorioretinopathy.² For the study, we used 126 mW of power with 15 ms duration for the 100% burns and 30% energy. An average of 532 spots were placed at 200 μ m each. The spacing between spots was 0.25 μ m. After 6 months of follow-up after a single treatment, 37% of patients required no further treatment, 44% needed one additional treatment, and 19% required two additional treatments. Three-quarters of patients had complete fluid resolution and 25% had at least partial fluid resolution. Central macular thickness resolved from an average of 350 μ m to about 300 μ m and there was about a 14-letter gain

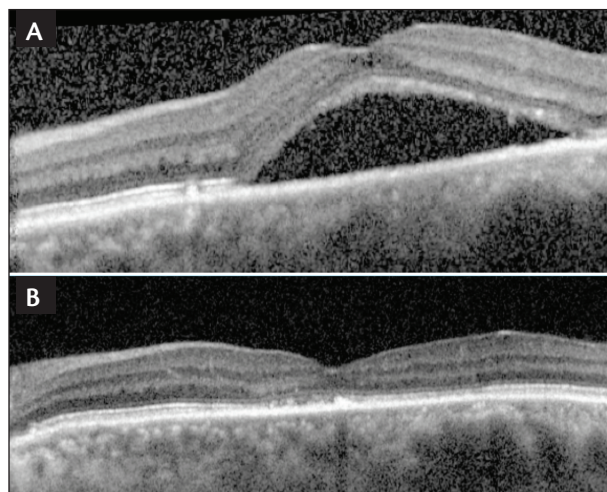


Figure 3. Pre-EpM visual acuity 20/60 (A); 1 year post-EPM visual acuity 20/20 (B).

in visual acuity from baseline.

There is follow-up data available for 21 eyes at 12 months; 16% of these eyes required no additional treatments through 12 months, and 57% and 27% needed one or two additional treatments. There was at least partial fluid resolution in all eyes, with complete resolution in 81%.

ENDPOINT MANAGEMENT PATIENT CASES

I use the PASCAL laser with Endpoint Management on many of my patients. Here are two patients who I have treated using EpM that I feel demonstrate the ability to provide a durable treatment, even in difficult cases.

Case 1

The first patient was a 61-year-old Caucasian female referred to my clinic with central serous chorioretinopathy. The visual acuity of her left eye was 20/60, and there was no history of recent ocular steroid or systemic medications. For this patient, we chose to use a 200 μ m spot size using 120 mW for 530 spots and 0.25 μ m spot distance.

Two months after treatment, there was still some fluid, but the visual acuity had improved to 20/25; by three months, the fluid was gone and the visual acuity was 20/20 (Figure 2). I have continued to follow this patient, and after 2 years, she has received only 2 treatments. It is well known that central serous retinopathy can be associated with frequent recurrence and poor visual outcomes, so I am satisfied with her outcome.

Case 2

A 46-year-old male was referred to me with nystagmus who had limited visual acuity since childhood, worsening during the previous 8 months due to central serous chorioretinopathy. This patient was very concerned about

receiving laser due to his eye movements and decided to wait. After 2 months, his anatomy deteriorated and we discussed performing treatment with EpM. I used a 200 μm spot size, 30% energy for 587 spots and 0.25 μm spot distance.

A treatment effect was clearly visible on an OCT just one month after a second treatment using the same parameters. However, the real result in this case was when I saw this patient 1 year later—the anatomy was completely resolved and the visual acuity was greatly improved (Figure 3). The patient stated that his vision was better than he had ever experienced. Needless to say, he was ecstatic with his treatment outcome.

CONCLUSION

Initial experience with EpM suggests it is safe for treating eyes with diabetic macular edema and central serous chorioretinopathy. There is now clinical

and experimental evidence that this treatment causes changes to the RPE and retina, resulting in a positive effect on the anatomy and visual acuity. Additional research will be needed to explore whether this technology will be useful in other indications and will help determine how best to use Endpoint Management in conjunction with pharmacologic treatments like anti-VEGF and corticosteroid injections. ■

Daniel Lavinsky, MD, is a professor of ophthalmology at Federal University of Rio Grande do Sul, Brazil. Dr. Lavinsky is a consultant for Topcon. Dr. Lavinsky may be reached at daniellavinsky@gmail.com.



1. Lavinsky D, Sramek C, Wang J, et al. Subvisible retinal laser therapy: titration algorithm and tissue response. *Retina*. 2014;34(1):87-97.

2. Lavinsky D, Palanker D. Nondamaging photothermal therapy for the retina: initial clinical experience with chronic central serous retinopathy. *Retina*. 2015;35(2):213-222.

Pattern Scanning and Non-damaging Laser Treatment in an Anti-VEGF Era

Successfully combining PASCAL, Endpoint Management and Anti-VEGF treatment protocols into my practice.

BY MANISH NAGPAL, MS, DO, FRCS; GUJARAT, INDIA

Many retina specialists will agree that PASCAL lasers (Topcon) have changed laser therapy. Rather than targeting a single spot, we can now target multiple spots, resulting in more uniform burns, decreased treatment time, increased patient comfort, and faster panretinal photocoagulation (PRP) on patients with edema. A new evolution in laser technology from PASCAL, Endpoint Management (EpM), allows surgeons to titrate the power and duration of laser spots to affect non-damaging and invisible laser spots, proffers to further enhance patients' experiences and outcomes. Since incorporating this technology into my practice, I have altered my approach to treating patients with macular disorders.

PATTERN SCANNING LASERS

A major advantage of pattern scanning lasers is that less fluence is needed because of the short pulse duration. A typical laser pattern requires about 127 joules/cm², whereas the PASCAL laser requires only 30 joules/cm². Additionally, the laser spot is uniform, resulting in less collateral damage (Figure 1). The operator can also customize the grid pattern to match the regional thickness when using the PASCAL laser. Another feature of the PASCAL laser is that the grid pattern is well controlled and repeatable, which yields a more predictable treatment response with less pain for the patient.¹

PHOTO-THERMAL THERAPY WITH EPM

EpM represents the next evolution in laser application. It provides the physician even greater control over the treatment and laser power delivered. When using EpM, the surgeon has the option to apply a laser spot at full power to determine a landmark registration. Then, the power is turned down to a predetermined level—usually to about 30% duty cycle—to create the grid pattern.

EpM represents the next evolution in laser application. It provides the physician even greater control over the treatment and laser power delivered.

The lower-powered laser spots are below the threshold at which retinal tissue is damaged; and yet, the thermal energy provided by the laser is sufficient to affect the tissue of interest.

In my opinion, the key thing that EpM offers is control. EpM performs photo-thermal stimulation using advanced algorithms that allow for treatment at nondestructive levels. The physician titrates to a desired endpoint and the PASCAL laser automatically delivers laser energy within the therapeutic boundary with barely visible or invisible burns. However, even though no or little damage is seen, recent studies have shown that there is some positive tissue disruption even at low levels.² Thus, the operator gains complete control over the power level delivered; when first using EpM in practice, barely visible laser burns can be applied so as to get acclimated with a slightly different way of performing laser therapy. Over time, the surgeon will gain greater confidence with the treatment effect, and invisible laser spots can be used as the endpoint of treatment.

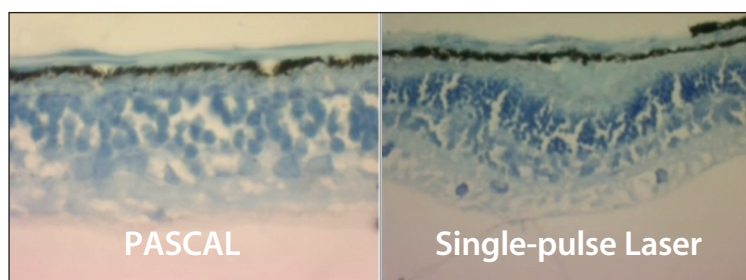


Figure 1. Short pulse duration image comparison with single-pulse laser.

The key thing that EpM offers
is control.

COMBINATION TREATMENT STRATEGIES BY DISEASE

Macular Edema

It is now well known that generalized edema (ie, sponge-like retinal thickening) responds well to a laser-based treatment, but that cystoid edema will not respond well to any amount of laser therapy (ie, the patient will be a nonresponder); in fact, the laser may increase inflammation. In such cases—as well as those of cystoid edema with subfoveal sensory fluid—the use of anti-VEGF injections are warranted to decrease the volume of the fluid and reduce the edema before considering a laser option (Figure 2). In cases where neither the laser nor the injection is working to reduce the edema, surgery may be necessary as an adjunct. Patients with well-defined circinates will respond well to a laser-based grid treatment, after which OCT can be used to determine whether the edema is recurring or if injections are required. If I determine that the patient is a good candidate for laser, I use my PASCAL with EpM.

The aim when treating patients with edema is to do the least possible damage to the macular area. In my opinion, the best option for achieving this is to use a treatment area with landmark patterns at the periphery and invisible spots in the grid. Using EpM, I would usually manifest a greyish white test burn outside the arcades and then reduce the settings to 40% of that setting. These parameters are then applied to a square or semi circular grid based on the extent of edema so as not to see visible burns except the landmarks, which define the areas of treatment.

Branch Vein Occlusions

The most common cause of visual loss in patients with a branch retinal vein occlusion (BRVO) is macular edema. It is well known that treatment is superior to observation in patients with BRVO,³ and subsequent studies have demonstrated that delayed initiation of treatment is associated with negative visual outcomes. Anti-VEGF injections, with or without laser, are the most common treatment approach for newly diagnosed BRVO.⁴ In fact, most cases respond well to treatment with an anti-VEGF agent; however, some patients may experience a recurrence. In these patients, I will use three loading doses of anti-VEGF injections and perform an EpM treatment at the time of the second injection.

Central Vein Occlusions

The level of ischemia will govern my treatment approach

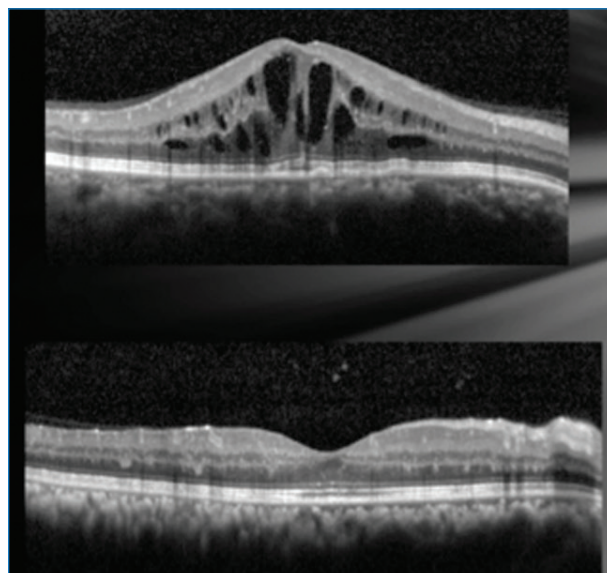


Figure 2. The patient presented with cystoid macular edema (A). Anti-VEGF therapy can be used in such patients to reduce the edema before applying laser (B).

in patients with central vein occlusion (CRVO). I prefer to use PRP on eyes with ischemic vein occlusions. For patients with nonischemic CRVO, I will opt for anti-VEGF or a dexamethasone intravitreal implant 0.7 mg (Ozurdex; Allergan). If there is a recurrence of edema then I would also perform light PRP in the periphery of these eyes. Eventually, if there is further recurrence, then I inject a second dexamethasone intravitreal implant 0.7 mg at the third month and perform an additional PRP procedure.

CONCLUSION

Using EpM, I can precisely control energy delivery to effect visible to non-visible burns and still be confident I am producing a beneficial therapeutic effect without causing long-term damage. This level of control over the laser treatment has allowed me to adjust my overall treatment approach to diseases such as DME, BRVO, and CRVO, combining the beneficial effects of pharmacologic therapy with carefully applied laser. ■

Manish Nagpal, MS, DO, FRCS (UK), is a senior consultant, Retina and Vitreous Services, at the Retina Foundation & Eye Research Center in Gujarat, India. Dr. Nagpal is a consultant and advisor for Topcon. Dr. Nagpal may be reached at drmanishnagpal@yahoo.com.



1. Nagpal M, Marlecha S, Nagpal K. Comparison of laser photocoagulation for diabetic macular edema using 532-nm standard laser versus multispot pattern scan laser. *Retina*. 2010;30:452-458.
2. Palanker D, Lavinsky D, Blumenkranz MS, Marcellino G. The impact of pulse duration and burn grade on size of retinal photocoagulation lesion: implications for pattern density. *Retina*. 2011;31(8):1664-1669.
3. Lavinsky D, Palanker D. Nondamaging photothermal therapy for the retina: initial clinical experience with chronic central serous retinopathy. *Retina*. 2015;35(2):213-222.
4. Rogers SL, McIntosh RL, Lim L, et al. Natural history of BRVO: an evidenced based systemic review. *Ophthalmology*. 2010;117(6):1094-1101.

Successful Patient Cases using Endpoint Management for DME

Endpoint Management enables reliable titration of laser to create nondestructive treatment of macular disorders.

BY MIHO NOZAKI, MD, PHD; NAGOYA, JAPAN

We have been using the PASCAL Laser (Topcon) at our institution in Nagoya, Japan, for a number of years. We consider it to be a significant breakthrough in laser treatment, as the pattern scanning laser allows us to perform meticulous procedures with minimal ancillary damage to ocular tissue. The ability to perform short pulse duration laser treatments with a high power setting provides a versatile tool to treat a variety of retinal diseases. This provides the ability to deliver less heat diffusion to the inner retina and choroid, which translates to less pain for the patient and less lateral expansion and less damage to inner retina.

Similar to how the PASCAL 577 laser expands the limits of possibilities in treating retina pathologies, I believe Endpoint Management (EpM, Topcon) is a technology breakthrough for delivering laser to the eye. EpM enables reliable titration of laser energy to create nondestructive treatment of macular disorders. With Landmark Patterns, the outer corners of a pattern can be selected to remain visible and provide reference points, while the remainder of the pattern can be subvisible. The procedure is repeatable, and the technique itself is easy to learn and can be quickly incorporated into practice.

The following two cases are examples of patients I treated in our clinic using EpM. In these cases, I do not believe I would have achieved the outcome without this important technology.

Case No. 1

A 75-year-old female developed diffuse diabetic macular edema (DME) after a vitrectomy with peeling of the epiretinal membrane and cataract surgery. Treatment was performed with a modified ETDRS grid laser, but there was residual retinal thickness and subretinal fluid after the procedure; her visual acuity was 0.6. Corticosteroid therapy was attempted but was also ineffective (it is plausible that the vitrectomy contributed to this).

In our opinion, EpM was the best option for this patient because her eye had already received vitrectomy. Additionally, eyes with subretinal fluid react well to EpM

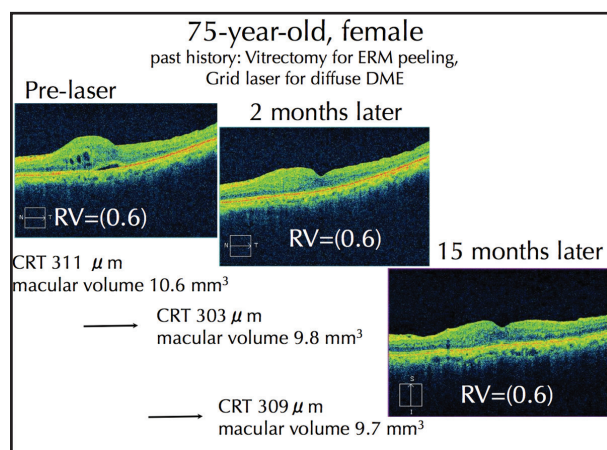


Figure 1. OCT scans before, 2 months, and 15 months after EpM laser treatment in a patient with diffuse DME. Central retinal thickness (CRT) was reduced from 311 μ m to 303 μ m, and remained at 309 μ m 15 months later.

treatment. We chose to use 200 mW of power at 50% for 15 ms pulses with a 200 μ m spot size and a spacing of 0.25 μ m. Fifteen months after a single treatment, retinal sensitivity improved dramatically compared with baseline. The subretinal fluid was decreased and retinal thickness was reduced (Figure 1).

Combination Therapy with EpM

DME remains a leading cause of blindness and it is well known that focal edema can be treated with a focal laser. However, there is not an agreed upon standard for treating diffuse edema. Anti-VEGF therapy is a viable first line treatment; yet studies show that multiple injections are necessary to achieve good outcomes. An interesting study by Kiss and colleagues suggested that patients with DME in the real world are receiving about 2.2 to 3.6 injections per year and about 57% receive either intravitreal steroid or laser.¹ My interpretation of this finding is that there is still a role for laser in these patients, and that it would be in our patients' interest to have a platform to provide a treatment that is tissue selective and is also minimally destructive. I believe laser treatment with

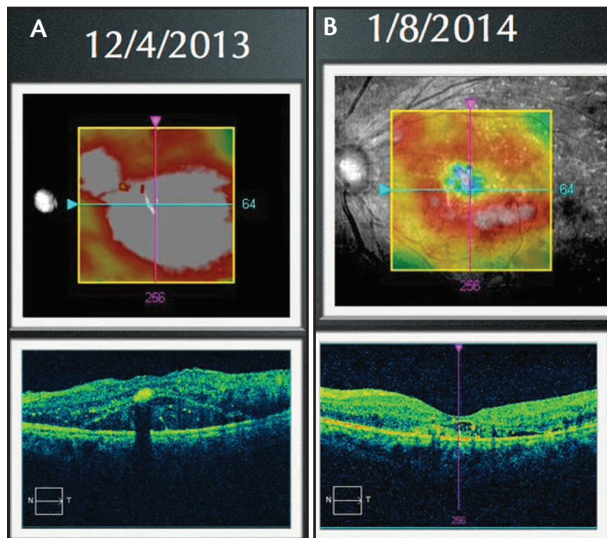


Figure 2. Laser with EpM yielded significant reduction of macular swelling and resolution of subretinal fluid after a single treatment, as shown at 1 month (B). After 1 year, there was no recurrence of the edema.

EpM is such a system.

Anti-VEGF therapy can reduce the retinal thickness very quickly, but to avoid recurrence of edema, additional treatment with EpM may be useful. In a very thick edematous macula, I usually inject anti-VEGF first and confirm the reduction of retinal thickness. Within 1 month, I treat these patients with EpM. We are currently conducting a prospective study with this protocol in Japan, Korea, Hong-Kong, and Singapore.²

Case 2

A 42-year-old female patient with residual DME after previous panretinal photocoagulation and steroid injection was referred to our clinic. Visual acuity was 0.1 and there was swelling of the retina with subretinal fluid on examination and imaging. FA showed areas of residual nonperfusion and diffuse macular leakage.

At first we attempted an additional steroid injection. One week later, we performed additional panretinal

Two months after a single treatment, retinal sensitivity improved dramatically compared with baseline.

photocoagulation, and, finished with treatment using Endpoint Management software over the macula. Two months later, there was minimal subretinal fluid and visual acuity had improved. At her next visit 1 year later, there was no recurrence after the single treatment, which demonstrates the durability of this treatment (Figure 2).

CONCLUSION

I will not deny that anti-VEGF therapy is a gold standard therapy for DME, but multiple injections cannot be used in a “real world” clinic. To reduce the number of anti-VEGF injections, adding laser treatments using EpM is a good strategy. We are conducting an ongoing prospective study comparing anti-VEGF monotherapy versus anti-VEGF and EpM. I look forward to seeing the benefits of combination therapy (anti-VEGF and EpM) for DME in the future.

Miho Nozaki, MD, PhD, is associate professor in the department of ophthalmology and visual science at the Nagoya City University Graduate School of Medical Sciences, Nagoya, Japan. She acknowledged no financial interest in the products or company mentioned herein. Dr. Nozaki may be reached at nozakim@med.nagoya-cu.ac.jp.



1. Kiss S, Liu Y, Brown J, Holekamp NM, et al. Clinical utilization of anti-vascular endothelial growth-factor agents and patient monitoring in retinal vein occlusion and diabetic macular edema. *Clin Ophthalmol*. 2014; 26;8:1611-1121.

2. Wong I. To compare anti-VEGF monotherapy with anti-VEGF and EpM grid laser combination therapy for diabetic macular edema (END-DME). <https://clinicaltrials.gov/ct2/show/NCT02462304?term=NCT02462304&rank=1>. Updated June 15, 2015. Accessed September 16, 2015.

RETINA TODAY